




Truth or Fiction:
Analysis of Patterned Injuries

Melinda Merck, DVM
Veterinary Forensics Consulting
Austin, Texas USA


1



Guarding Against Bias

- Impt to be objective: thought process, analysis
- Tendency to use mental short cuts, heuristic thinking with information overload
- Prefer less complex
- May believe witness accounts vs. consideration
- Confirmation bias: believe pos vs neg, give less weight to neg info
- Anchor effect: rely heavily on one piece of info, usually first info encountered

2



Guarding Against Bias

- Investigations conducted in confirmatory manner: incr confidence of theory vs. maintaining objectivity, reduce consideration of all information
- Review all info several times
- Consider alternate theories – disprove/support
- Document neg evidence
- **Discussion:** peers, investigator, attorney

3

Measurements

Common mistake is lack of photo scale; if weapon, need distortion correction scale

Use other items in photo if no photo scale

Send back to get measurements of items

4

Thermal liquid and Scald burns

Scalding/Thermal: no hair singeing; splash/spill – fluid cools as it flows due to gravity and gets less severe burn

Deliberate immersion – straight burn line by fluid level, possible struggle/splash burns

Thermal burns often cause deeper injury than chemical burns

5

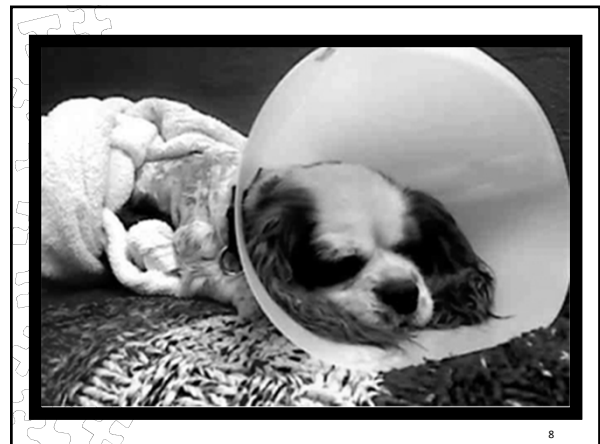
Chemical Burns

Consider contact points through animal action

Variable skin injury to: muzzle, paws, legs

Oral cavity – if licked, ingested

6



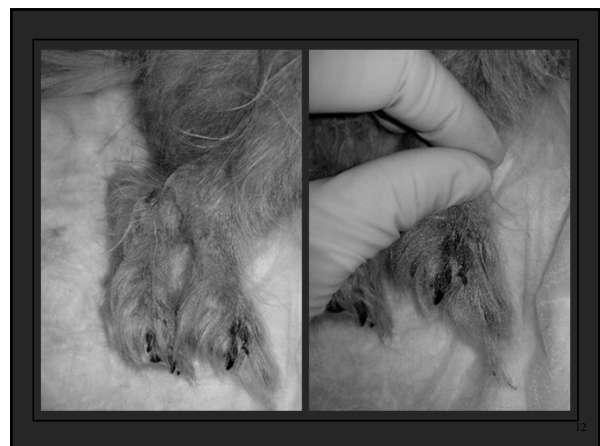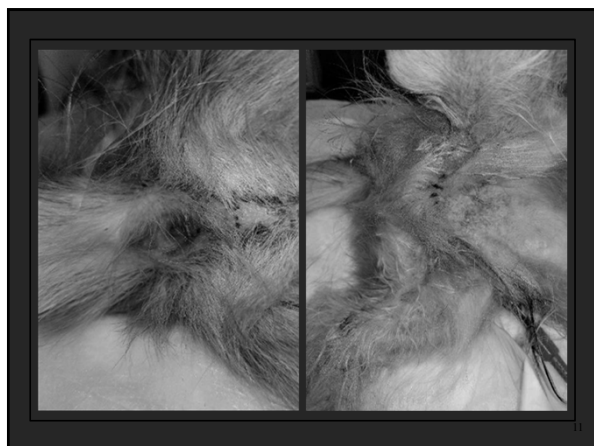Case Analyses:
Put Your
Sherlock
Hat On...

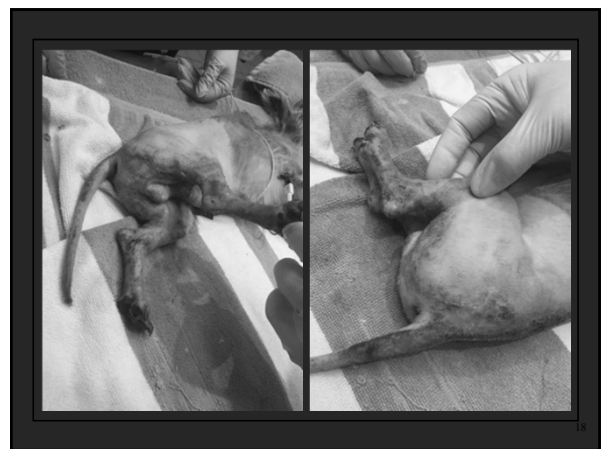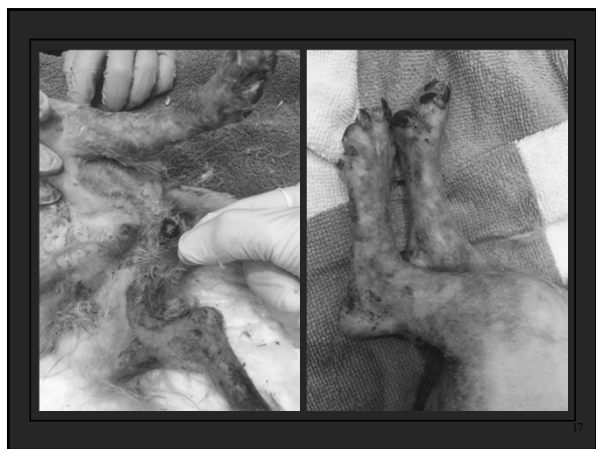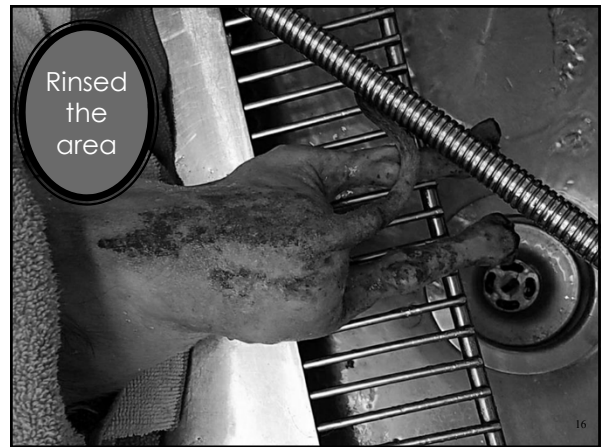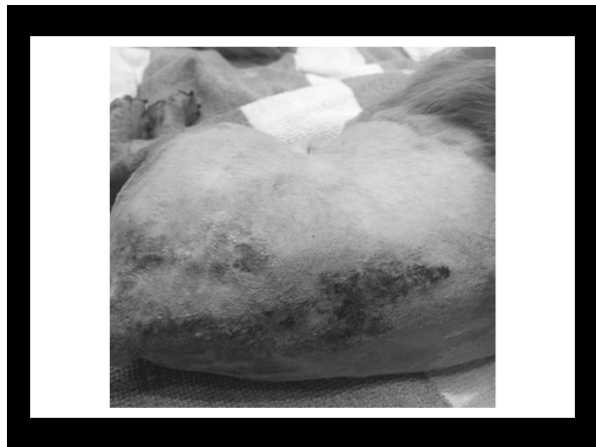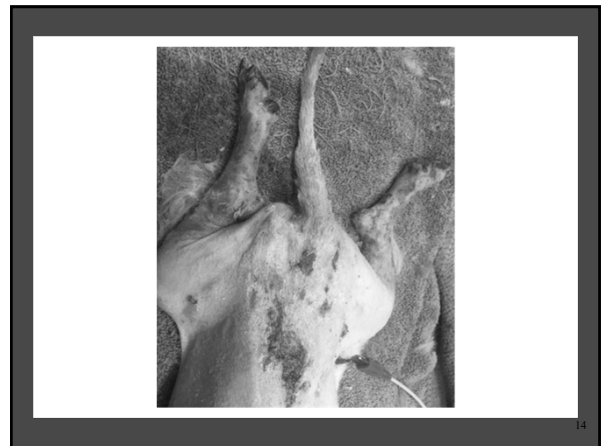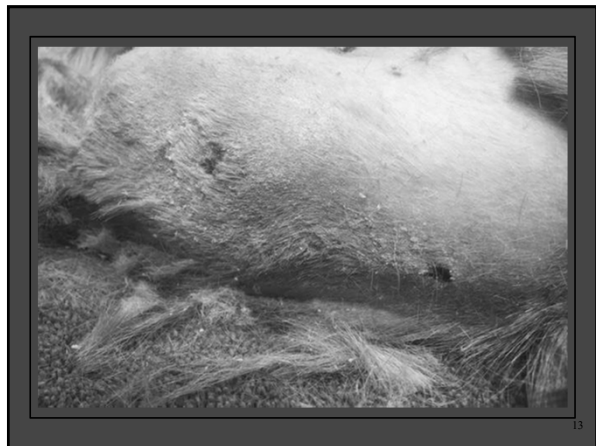9

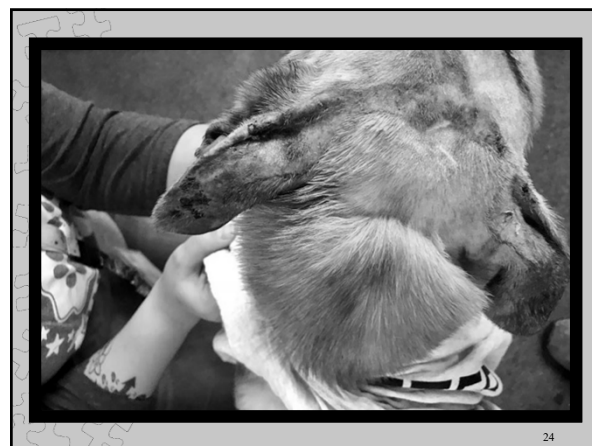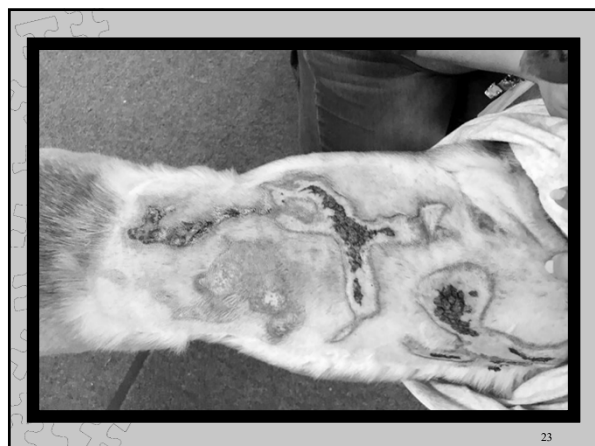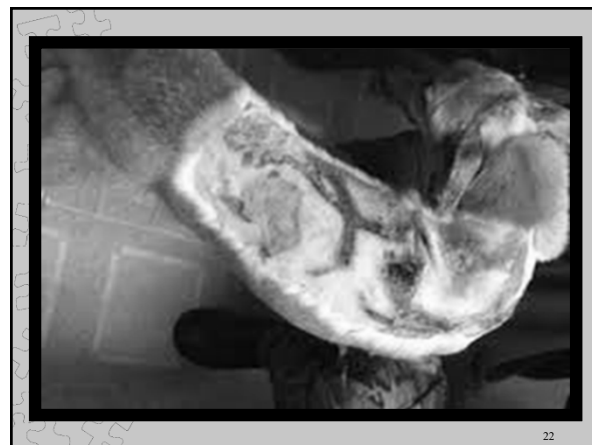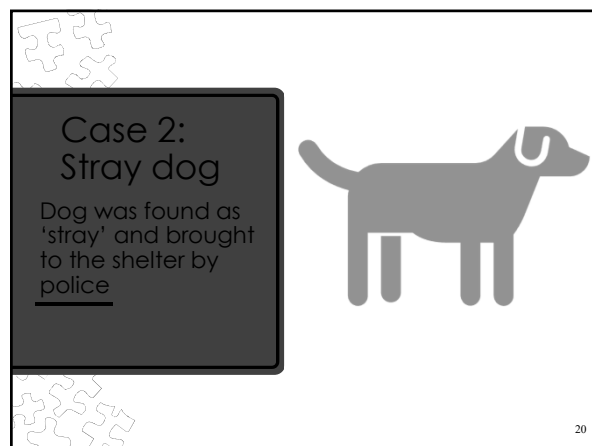
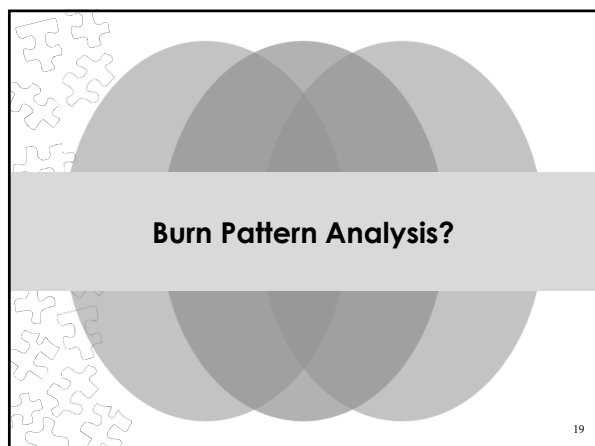
Case 1: 'We just got the dog'

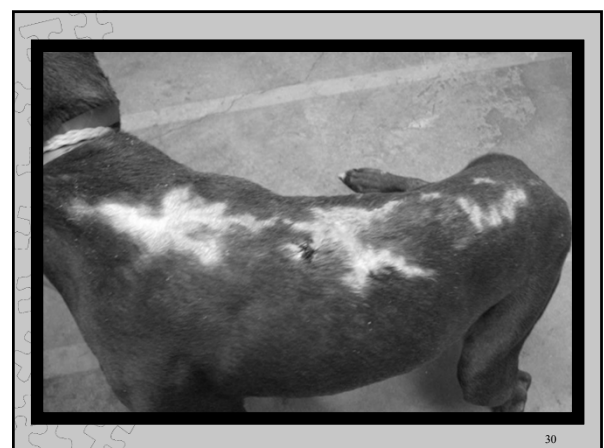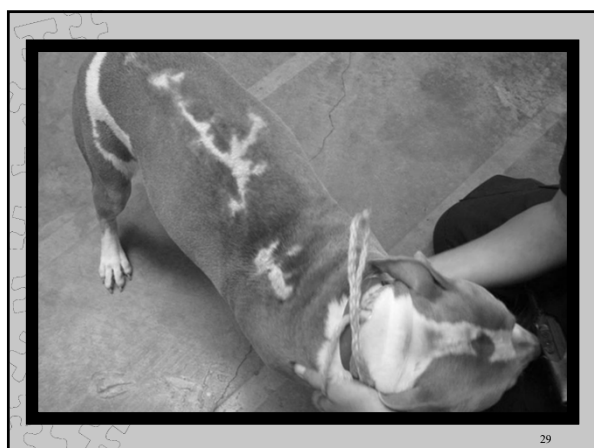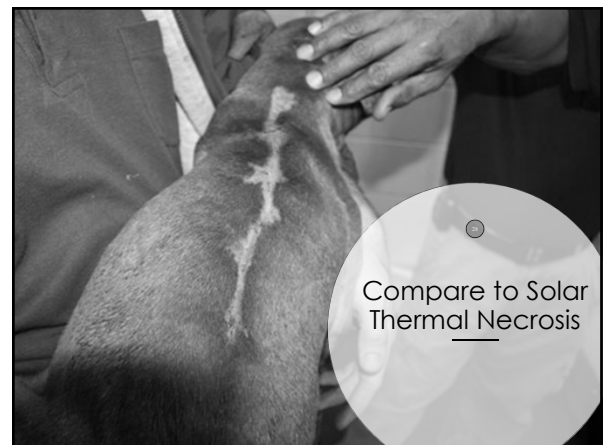
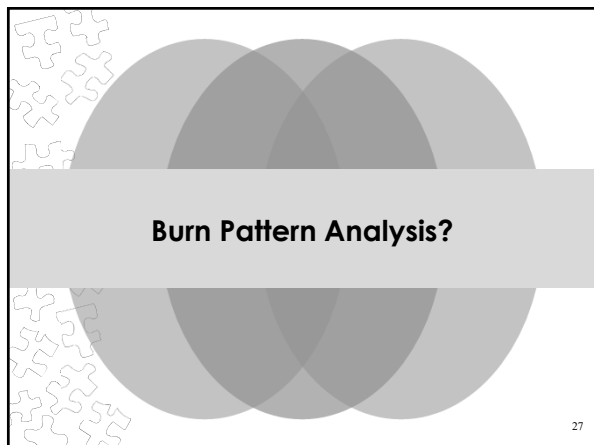
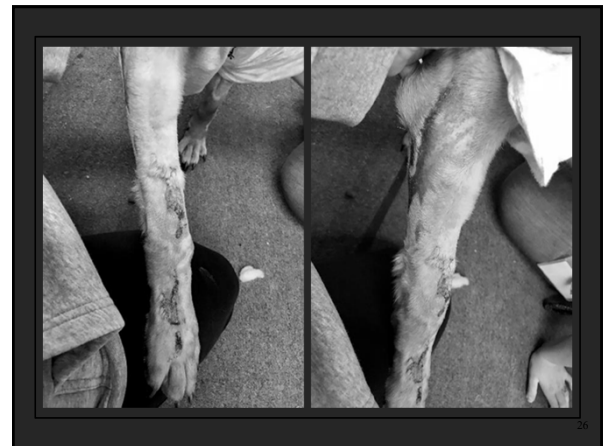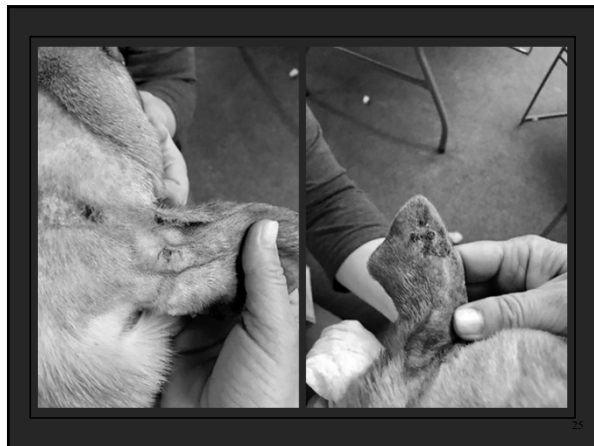- Brought small breed juvenile dog to vet – just started having difficulty walking
- Claimed just had him a few days and got from someone else in another state
- Vet exam: burns on legs, parts of caudal back and tail
- Questions: what caused the burns?

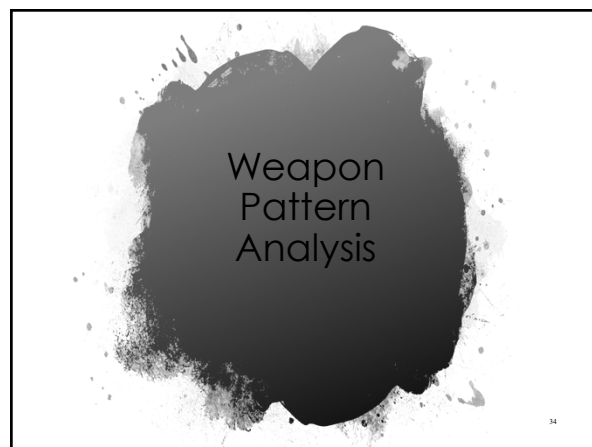
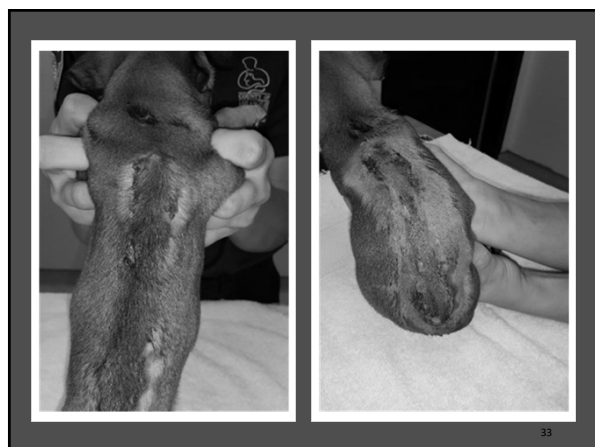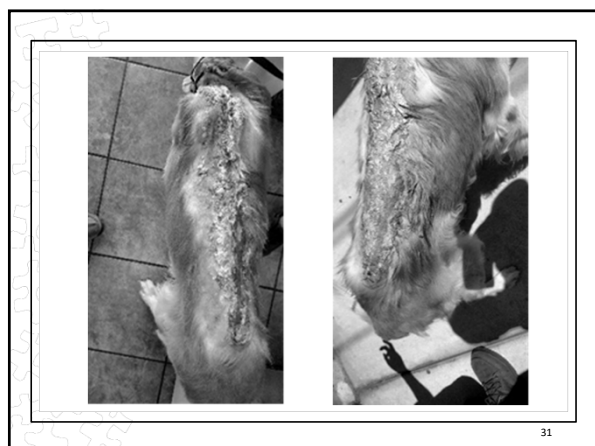
10











Considerations for Weapon Type Determination

- Look at denser area of hemorrhage for clues to pattern
- May have clear central areas where compression forced blood to outer edges
- Look at bone/cartilage for pattern imprints
- If cylindrical – consider where would impact could be smaller full width
- Describe weapon type, characteristics. If weapon known may say 'consistent with'

35



Knife Wounds

Appearance depends on skin properties, nature and type of knife, movement of victim, movement of knife in body

If part dull, may have abraded/contused areas

Beveled margins and undermined tissue opposite if enters obliquely

Knife characteristics may be imparted to surface, wound margins, wound track

37


Knife Wounds

If full penetration, entrance wound may be squared at both ends

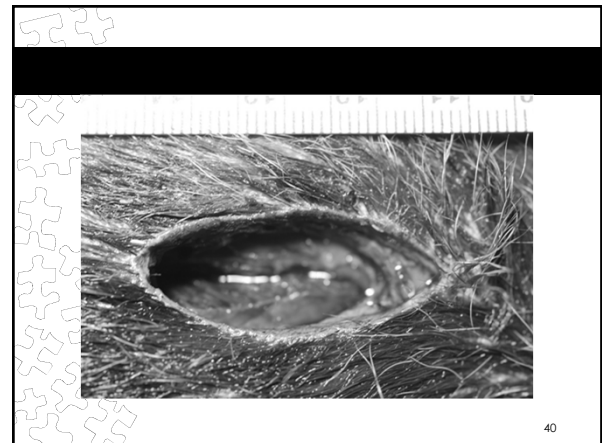
Serrated – may see striations on entrance wound margins if entered obliquely; wavy or scalloped patterns on superficial cuts, shallow wounds, organ wound tracks

Knives can have serrated portions – describe as 'impact with serrated portion of blade'

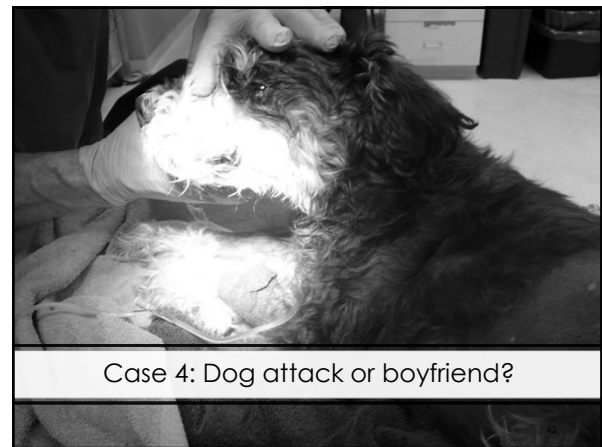38



39



40



Case 4: Dog attack or boyfriend?

Case Info

Owner of miniature (Elvis) and two giant schnauzers

Came home and found Elvis inside crate with door ripped off; blood around mouth; 'intestines' protruding from abdomen

Boyfriend home at the time and claimed nothing happened; kicked owner in leg; boyfriend is drug user

Took to ER, told vet she suspected boyfriend but needed to know if other dogs attacked Elvis

43

ER vet: clean margins along external perforating linear wound, appx 2cm long with omentum pulled out; internal linear wound in abdominal wall 1.5cm long exploratory laparotomy – no internal organ damage or bruising as would expect from dog attack; some unusual abrasions on external abdomen that are inconsistent with teeth or nail abrasions. But – **he did not tell owner it was not a dog attack because felt uncomfortable**

Dog transferred to other hospital for continued care; owner informed tech about her suspicions and her own injuries from boyfriend

I was called in to examine dog

44



Photo L1060567: Bruising left side of face

45

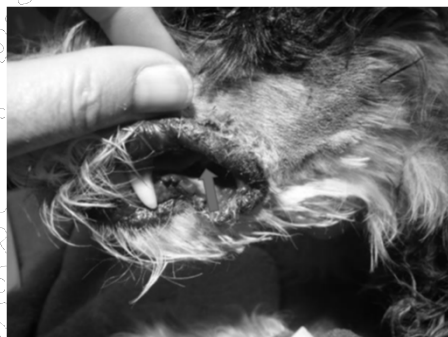

Photo L1060566: blue arrow - laceration on left lip

46



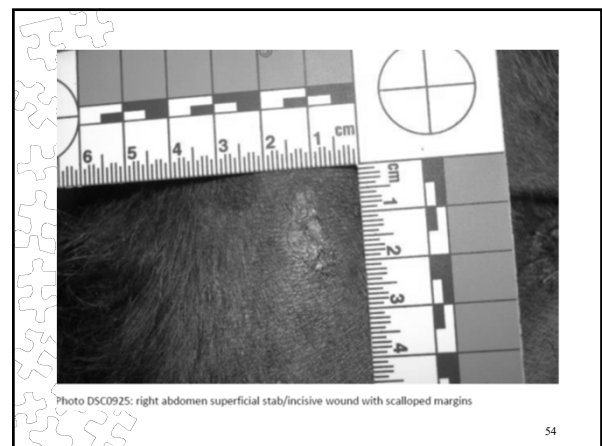
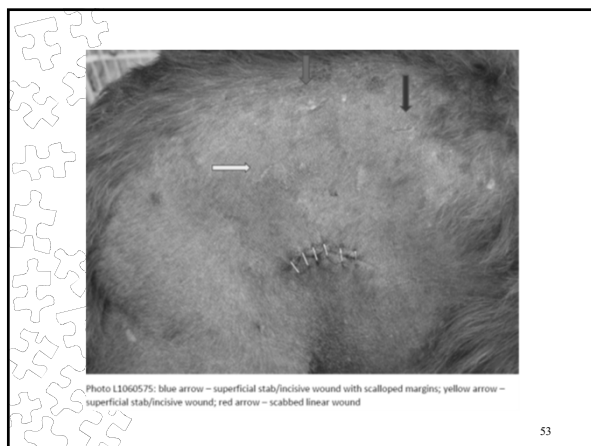

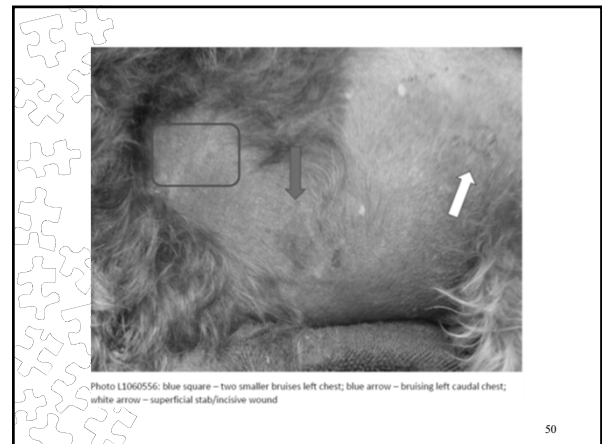
Photo L1060570: blue arrow - abrasion left upper lip

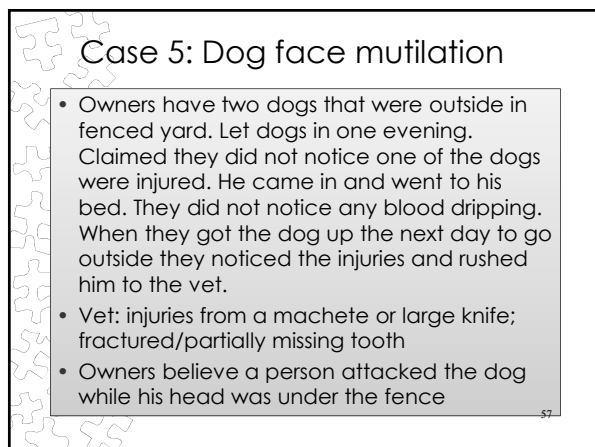
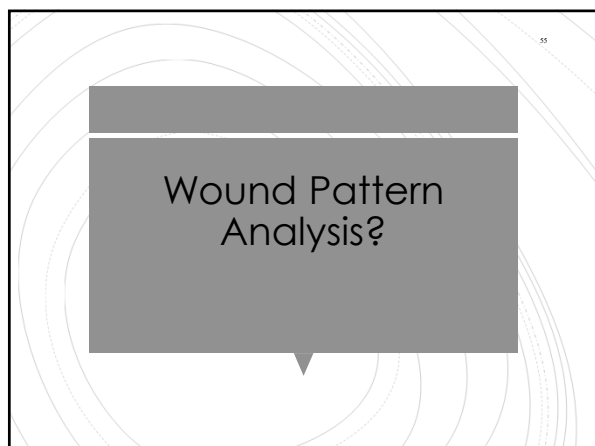
47

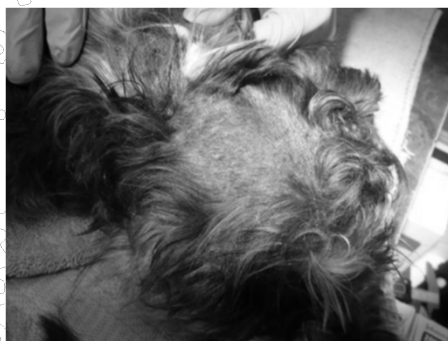

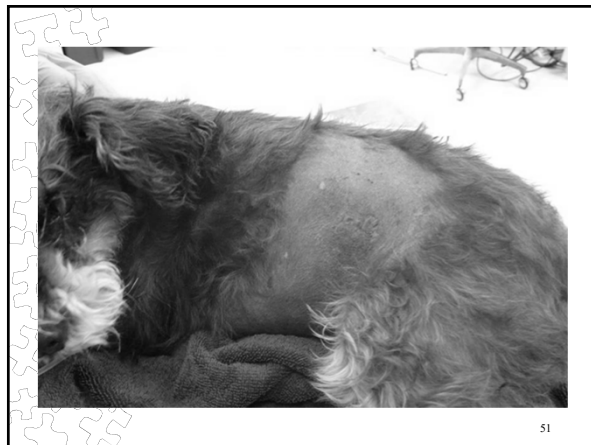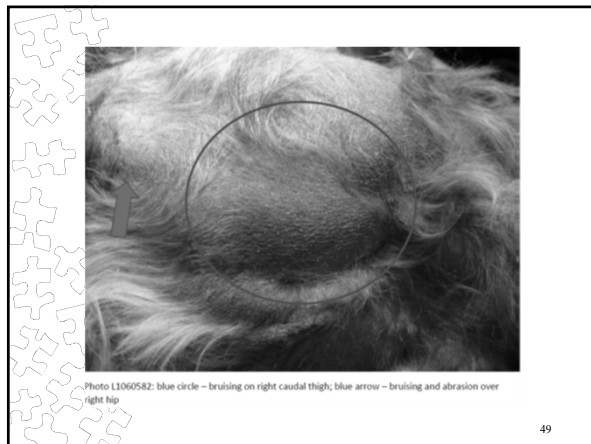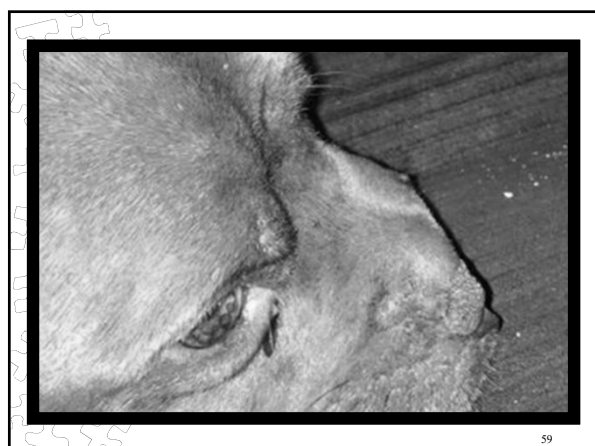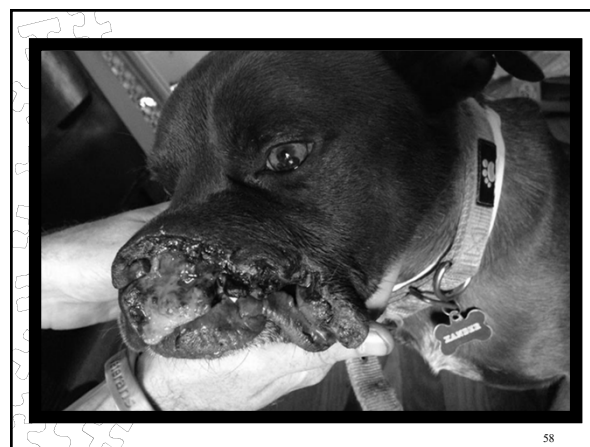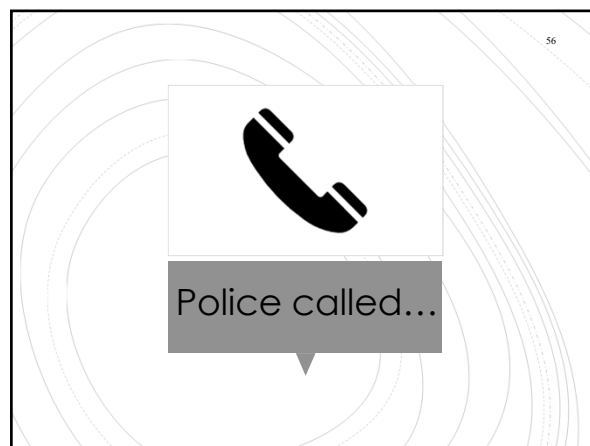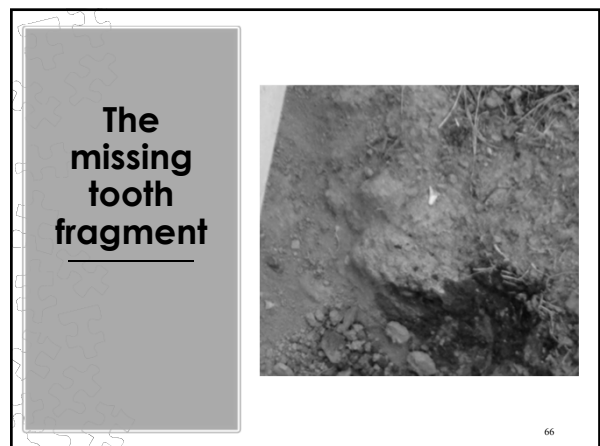Photo L1060578: bruising above right eye, in front of right ear

48







**The
missing
tooth
fragment**

